Neuroscience 8th Batch Final Answered

MCQs (100)

Note : Please note that we're not sure of the answers that are highlighted in red

1. A 30-year-old woman complains of unsteadiness while standing and walking. She tends to deviate to the left. Neurological examination reveals dysmetria on the left side, dysdiadokokinesia, and nystagmus that is more marked when she looks to the left side. Where is the lesion located?

A. Right cerebellar hemisphere
B. Left cerebellar hemisphere
C. Left globus pallidus
D. Left striatum
E. Right substantia nigra

Correct answer is B

2. A 50-year-old hypertensive woman complains of numbness and weakness in her left leg and foot. Occlusion of which of the following vessels may account for this complaint?

A. Anterior choroidal artery
B. Internal carotid artery
C. Anterior cerebral artery
D. Middle cerebral artery
E. Posterior cerebral artery

Correct answer is C

3. A 40-year-old dentist complains of headaches and inability to control his walking (gait). Neurological examination reveals loss of hearing on the right side and tinnitus, vertigo and nausea, wide based ataxic gait and lurching on the right side. Which one of the following is most likely involved in this case?

A. Cerebellopontine angle
B. Medial pons
C. Lateral medulla
D. Medial medulla
E. Lateral pons

Correct Answer is C

Use the following scenario for the questions 4 and 5

A 60-year-old patient with sudden onset of abnormal movements in his right limbs came to KFSHRC. He had increased appetite and hyperphagia and also developed mood and behavioral changes. Mental status and cranial nerves function was normal. In examination of motor system, no abnormality was detected in muscle tone; and force of extremities was normal. Deep tendon reflexes were symmetric and no pathologic reflexes were found. Involuntary movements, including continuous, arrhythmic and purposeless choreiform movements with occasional brisk proximal ballistic movements were seen affecting both upper and lower limbs on the right side with the same severity. The MRI showed an infarct in the sub-thalamic region.

4. He is suffering from which of the following conditions?

A. Parkinson's disease
B. Huntington's chorea
C. Alzheimer's disease
D. Hemiballismus
E. Sydenham's chorea

Correct answer is D

5. The infarct in this case is due to occlusion of a branch of which one of the following arteries?

A. Anterior cerebral
B. Middle cerebral
C. Posterior cerebral
D. Anterior communicating
E. Posterior communicating

Correct answer is C

6. A 20-year-old has an inherited progressive neuronal degeneration of brain. This results in twitching movements of head, grimacing movements in face, lips and tongue, gesticulating movements in distal parts of upper limbs and jerking movements in distal parts of lower limbs. The neurons in which one of the following parts of the brain were degenerated in this case?

A. Globus pallidus externa
B. Subthalamus
C. Substantia nigra compacta
D. Striatum
E. Globus pallidus interna

Correct answer is D

7. Spina bifida results from failure of fusion of:

A. Anterior neuropore
B. Posterior neuropore
C. Vertebral arches
D. Vertebral bodies
E. Neural tube

Correct Answer : C

8. During development of medulla, the general visceral efferent column differentiates into which of the following nuclei?

A. Ambigus
B. Dorsal vagal
C. Hypoglossal
D. Cochlear
E. Solitarius

Correct Answer is B

9. If the skull fails to develop, meninges and neural tissue may protrude over the head. This condition is known as:

A. Meningocele
B. Meningomyelocele
C. Meningoencephalocele
D. Meningohydroencephalocele
E. Meningocystocele

Correct Answer : C

10. The CT scan below shows an area of infarct. Occlusion of which one of the following arteries can lead to this finding?

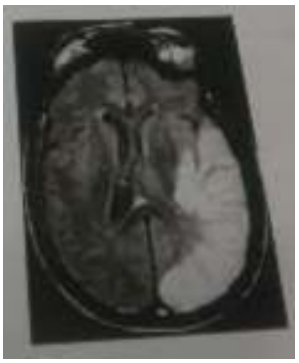

A. Anterior cerebral
B. Middle cerebral
C. Posterior cerebral
D. Superior cerebellar
E. Posterior choroidal

Correct answer is B

11. Stimulation of the frontal oculomotor area (area 8) would most likely produce:

A. Contraction of the muscles of the contralateral legs
B. Visual agnosia
C. Auditory hallucinations
D. Conjugate eye movements
E. Fasciculations in the muscles of the ipsilateral hands

Correct answer is D

12. Which of the following connects Wernicke's area in the temporal lobe to Broca's area in the frontal lobe?

A. Inferior longitudinal fasciculus
B. Uncinate fasciculus
C. Arcuate fasciculus
D. Corona radiata
E. Cingulum

Correct ans is C

13. An impairment in the ability to perform certain types of learned, complex movements (referred to as apraxia) usually results from a lesion of which of the following?

A. Precentral gyrus
B. Postcentral gyrus
C. Premotor cortex
D. Prefrontal cortex
E. Primary motor cortex

Correct ans is C

14. The vascular structure found around the attachment of the falx cerebri with the tentorium cerebelli is the:

A. Sigmoid sinus
B. Superior sagittal sinus
C. Inferior petrosal sinus
D. Transverse sinus
E. Straight sinus

Correct ans is B

15. A 67-year-old woman suffered a cerebral infarction 3 weeks ago. She frequently forgets to put her left arm into the sleeve of her blouse, always leaves food on the left side of her plate, and frequently bumps into things on her left side. She has no language disorder or paralysis of speech. Which of the following represents the most likely site of cerebral cortical damage in this patient?

A. Motor cortex in the right hemisphere
B. Posterior parietal cortex in the right hemisphere
C. Posterior parietal cortex in the left hemisphere
D. Inferior temporal cortex in the right hemisphere
E. Inferior temporal cortex in the left hemisphere

Correct answer is B

Use the following clinical scenario for questions 16-18

Mrs. Khan, a 64-year-old lady, with a history of diabetes, hypertension, peripheral vascular disease and coronary artery disease presented to the ER with vomiting, vertigo and gait unsteadiness. She also started having hoarseness of voice and was brought to the ER soon after. On examination, her vitals were: pulse 95/min, BP 220/100, temp= 37. Her initial neurological examination showed left sided Horner's Syndrome and loss of pain and temperature sensation on the left side of the face and the right side of the body. Weakness of palate, pharynx and vocal cords was noted on the left, along with left sided cerebellar ataxia.

16. Which if the following tracts in involved in Horner's syndrome?

A. Corticospinal
B. Spinocerebellar
C. Hypothalamospinal
D. Spinothalamic
E. Tectospinal

Correct answer : C

17. Left sided cerebellar ataxia was noted due to damage to which of the following?

A. Left cerebellum
B. Left cochlear nucleus
C. Left inferior cerebellar peduncle
D. Left principal sensory nucleus
E. Left spinal trigeminal tract and nucleus

Correct answer : C

18. Left sided weakness of palate, pharynx and vocal cords was noted because of damage to which of the following?

A. Nucleus ambiguus
B. Nucleus cuneatus
C. Nucleus dorsalis
D. Nucleus gracilis
E. Nucleus solitarius

Correct answer : A

19. Which of the following cranial nerve nuclei is responsible for the salivary secretion from the parotid gland?

A. Edinger-Westphal nucleus
B. Inferior colliculus
C. Superior colliculus
D. Inferior salivatory nucleus
E. Superior salivatory nucleus

Correct answer : D

20. What is the most sensitive sign on non-contrast CT for detecting early hydrocephalus?

A. Cortical sulcal effacement
B. Uncal herniation
C. Enlarged third ventricle
D. Enlarged fourth ventricle
E. Enlarged temporal horns of lateral ventricles

Correct Answer : E

21. A 70-year-old diabetic presents with slurred speech and right sided weakness, which spontaneously resolved over 1-2 hours. Initial unenhanced CT is normal. Further investigation by MRI is requested. What sequence is most sensitive for diagnosing acute ischemia in the brain?

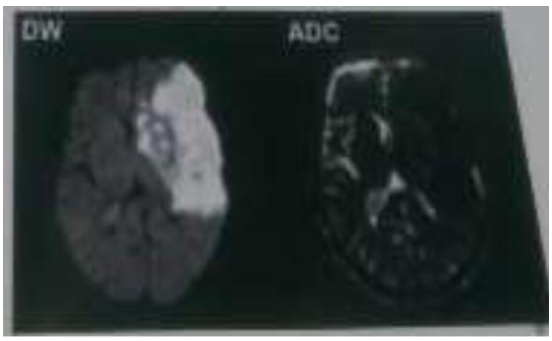

A. T2 W1
B. T1 W1 post-Gadolinium
C. Diffusion weighted imaging
D. FLAIR
E. Proton density

Correct Answer: C

22. A 70-year-old male with a low score on the Glasgow coma scale is admitted to a medical assessment unit. MRI shows a large area in the left MCA distribution returning high signal on diffusion-weighted images and low signal in the corresponding area on the ADC map. The most likely diagnosis is:

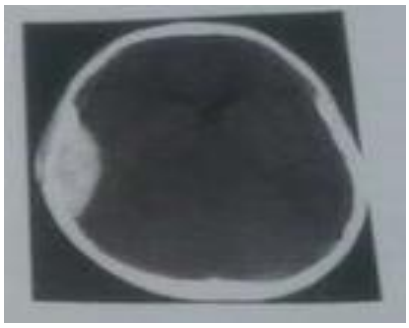

A. Acute hypertensive bleed
B. Acute cerebral infarction
C. Old cerebral infarction
D. Sagittal sinus thrombosis
E. 14-day old cerebral infarction

Correct ans is B

23. A 30-year-old man with a history of medically refractory partial seizures undergoes MRI examination as work up for epilepsy. Coronal T2 W1 shows left hippocampal atrophy with prominent temporal horn of the lateral ventricle (white arrow in image). Which condition is most likely to result in such a pattern of volume loss?

A. Pick's disease
B. Encephalitis
C. Parkinson's disease
D. Medial temporal sclerosis
E. Temporal lobe infarction

Correct ans is D

24. A 28-year-old unconscious man was admitted to the Accident & emergency department after a motorcycle accident. He briefly regained consciousness and then became comatose. CT of the head shows a fracture of the right petrosal bone with mild midline shift. Which of the following best describes the hemorrhage?

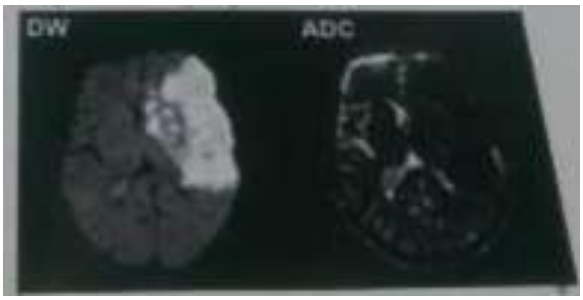

A. Acute subarachnoid
B. Acute subdural
C. Acute extradural
D. Acute intracerebral

Correct answer : C

25. A 35-year-old woman with spastic paraparesis presents with an episode of right facial paralysis. A FLAIR axial image of the brain and a contrast enhanced T1 image of the cervical spine and shown below. What is the most likely diagnosis?

A. Multifocal hemorrhage
B. Vasculitis
C. Multiple sclerosis
D. Transverse myelitis
E. Small vessel ischemic disease

Correct ans is C

26. Increased neural activity before the onset of a skilled voluntary movement is first seen in which of the following?

A. Midbrain
B. Cerebellum
C. Precentral motor cortex
D. Spinal alpha motor neurons
E. Cortical unimodal association areas

Correct ans: C

27. Which of the following cortical functions is the most lateralized in humans?

A. Vision
B. Hearing
C. Writing
D. Language
E. Handedness

Correct answer : D

28. The axons of which of the following cortical cells project to cerebellar nuclei in order to influence outflow?

A. Golgi
B. Basket
C. Stellate
D. Purkinje
E. Granular

Correct Answer: D

29. Patients with Parkinson's disease may obtain symptomatic relief from which of the following?

A. Increasing dopamine levels in the striatum
B. Increasing acetylcholine levels in the striatum
C. Increasing GABAergic stimulation of GPe
D. Increasing the tonic drive from GPi to motor thalamus
E. Blocking glutamatergic input from the cortex to the striatum

Correct ans is A

Use the following clinical scenario for questions 30-32

A 21-year-old man has been using a banned substance containing a contaminant toxin that is known to selectively destroy groups of neurons in the brainstem. He presented with tremors and rigidity.

30. Which of the following neuronal groups in the brainstem might be related, either directly or indirectly, to this person's condition?

A. Vestibular nuclei
B. Substantia nigra
C. Trigeminal spinal nuclei
D. Dorsal column nuclei
E. Raphe nuclei

Correct Answer is B

31. The neurotransmitter loss most likely linked to the symptoms is?

A. Acetylcholine
B. Dopamine
C. Glycine
D. Norepinephrine
E. Serotonin

Correct Answer is B

32. A common approach toward the treatment of this disorder would be to administer:

A. A serotonin reuptake inhibitor
B. A CNS depressant
C. A dopaminergic agonist
D. A noradrenergic antagonist
E. An NMDA blocker

Correct Answer is C

33. Which of the following would you expect to observe as a result of bilateral loss of hippocampal function?

A. Disappearance of semantic memory
B. Loss of working memory
C. Loss of the ability to encode events of the recent past in long term memory
D. Loss of the ability to recall faces and forms but not the ability to recall printed or spoken words
E. Production of inappropriate emotional responses when recalling events of the recent past

Correct answer is B or D

34. You are examining a 40-year-old male with recent complaints of poor memory. He is presented with a string of randomly ordered numbers which he is then asked to repeat. Which of the following types of memory are you testing?

A. Immediate
B. Working
C. Implicit
D. Semantic
E. Episodic

Correct answer is A

35. You are examining a 42-year-old woman with recent complaints of poor memory. She is asked to itemize what she did before going to bed last night. Which of the following types of memory are you testing?

A. Immediate
B. Working
C. Implicit
D. Semantic
E. Episodic

Correct answer is E

36. Encoding of new memory in the hippocampus requires long term potentiation of synaptic functions. Which of the following neurotransmitters is essential in the initiation of this process?

A. Nitric oxide
B. Glutamate
C. Acetylcholine
D. Dopamine
E. Norepinephrine

Correct answer is B

37. During periods of relaxed wakefulness with closed eyes, a normal individual's EEG will display a predominance of which of the following EEG rhythms?

A. Spike and wave rhythm
B. A wave
C. B wave
D. Δ wave
E. Θ wave

Correct Answer is B

38. Electroencephalographic waves maybe recorded from the brain when electrodes are placed on the scalp. Which of the following is the primary source of the recorded electoral activity?

A. Synaptic potentials from cortical pyramidal cell dendrites
B. Action potentials from cortical pyramidal cells
C. Synaptic potentials in cerebellar cortex
D. Action potentials from deep nuclei of cerebral cortex
E. Electrical activity in thalamic sensory nuclei activated by the ascending reticular activating system

Correct Answer is A

39. Which of the following EEG rhythms, if recorded from an awake young adult, will be indicative of serious brain damage?

A. Alpha rhythm
B. Beta rhythm
C. Theta rhythm
D. Delta rhythm
E. Gamma rhythm

Correct Answer is D

40. Which of the following stages of sleep is associated with the most synchronized EEG pattern?

A. Stage 1
B. Stage 2
C. Stage 3
D. Stage 4
E. REM

Correct ans is D

41. A patient is confused and displays localized jerks in his right hand, which progress to jerks of entire arm with a brief loss of consciousness. This disorder can best be characterized as a:

A. Generalized seizure
B. Absence seizure
C. Tonic seizure
D. Simple partial seizure

E. Complex partial seizure

Correct ans is E

42. Which of the following is a feature of cardio-embolic stroke?

A. Usually sudden in onset
B. Lasts for less than 24 hours
C. Leaves no residual deficit
D. Usually subcortical (white matter) involvement
E. Is not hemorrhagic

Correct ans is E

43. Which of the following is a risk factor for venous sinus thrombosis?

A. Infection
B. Dehydration
C. Hypercoagulable state
D. Male gender
E. Vasculitis

Correct answer is C

44. In decerebrate posturing:

A. Elbows and the knees are extended
B. Elbows are flexed and the knees are extended
C. Elbows are extended and the knees are flexed
D. Elbows and the knees are flexed
E. Elbows and the knees are in neutral position

Correct answer is A

45. Which of the following hemorrhages has a lens (concave) shape on a brain CT scan?

A. Intracerebral
B. Subdural
C. Epidural
D. Subarachnoid
E. Intrathecal

Correct answer : B

46. If a patient withdraws from painful stimuli, his motor response in Glasgow Coma Scale will be:

A. 1
B. 2
C. 3
D. 4
E. 5

Correct ans is D

47. A 54-year-old man with 3 months history of headaches in brought to the emergency department following a generalized tonic-clonic seizure. On physical examination, he has weakness on the right side. An MRI of his brain shows a large, irregular, 6 cm mass in the left cerebral hemisphere that extends across the corpus callosum. A stereotaxic biopsy of the mass is done and histological findings are shown in the figure. Which of the following neoplasms does he most likely to have?

A. Meningioma
B. Medulloblastoma
C. Hemangioblastoma
D. Glioblastoma multiforme
E. Diffuse large B-cell lymphoma

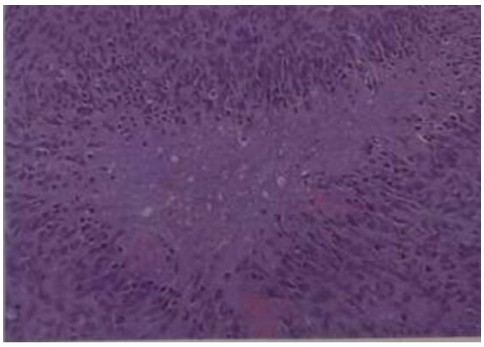

Correct answer : D

48. A 65-year-old woman who fell to the ground and hit her head, is taken to the emergency department. Physical examination is unremarkable. CT scan of the head shows no hemorrhage or fracture, but there is a 5cm mass beneath dura that compresses the underlying right parietal lobe. The mass is surgically removed. Histologic sections from the mass would most likely reveal:

A. Antoni A areas and Antoni B areas with Verocay bodies
B. Whorls of meningoepithelial cells and scattered psammoma bodies
C. Endothelial proliferation and nuclear pseudopalisading around necrotic area
D. Fried-egg appearance of tumor cells with scattered calcification
E. Sheets of anaplastic small blue cells with Homer-Wright rosettes

Correct answer : B

49. A 48-year-old man presented to ENT department with history of tinnitus and diminished hearing for the past 6 months. On physical examination, he has decreased hearing on both sides. A head MRI shows bilateral sharply circumscribed, 2-3 cm masses in cerebellopontine angle. Family screening reveals a similarly affected 32-year-old sibling. An inherited mutation involving which of the following genes is most likely to be present in this patient?

A. NF2
B. EGFR
C. FAP
D. TSC1
E. VHL

Correct answer : A

50. A 72-year-old alcoholic woman had problems in remembering things for past one year. Her immediate family members noticed that she confabulates quite often. She dies as consequence of hepatic failure. At autopsy, morphological changes are seen in mammillary bodies and medial dorsal nucleus of the thalamus. Which of the following is the most likely diagnosis in this case?

A. Pick disease
B. Multiple system atrophy
C. Central pontine myelinolysis
D. Wernicke-Korsakoff syndrome
E. Metachromatic leukodystrophy

Answer :D

51. A 30-year-old woman is brought to the hospital after an episode of weakness. On examination, she has decreased strength in her left upper extremity and decreased light touch sensation over her right lower extremity. She has no decrease in mentation. A lumbar puncture is performed, and the CSF contains elevated levels of IgG and oligoclonal bands on gel electrophoresis. Which of the following pathologic findings in CNS is she most likely to have?

A. Gliosis with atrophy of caudate and putamen
B. Loss of pigmented neurons in the substantia nigra
C. Perivascular lymphocytes with demyelinated axons in white matter
D. Increased neurofibrillary tangles and neuritic plaques in the neocortex
E. Foci of multinucleated cells and macrophages in grey and white matter

Correct ans is C

52. A 46-year-old man stuck his head against the wind shield of his van in a roadside accident. He lost consciousness at the time or at any point thereafter. Physical examination showed minor ?!in his forehead. However, 6 weeks later, he begins complaining of headaches and becoming irritable. Which of the following intracranial vascular abnormalities most likely developed in this man?

A. Epidural hematoma
B. Subdural hematoma
C. Intracerebral hematoma
D. Subarachnoid hemorrhage
E. Intraventricular hemorrhage

Correct answer : B

53. A 68-year-old man is undergoing hip joint replacement for long standing osteoarthritis. During this procedure, his systolic blood pressure drops to 50 mmHg that persists for 20 min despite intervention with pressor agents. Which of the following pathological lesions is most likely to occur in his brain as a consequence of this prolonged hypotensive episode?

A. Diffuse axonal injury
B. Linear parasagittal infarction
C. Lacunar infarcts of basal ganglia
D. Parietal lobe hemorrhagic infarction
E. Duret hemorrhage in midbrain and upper pons

Correct answer : B

54. A 58-year-old man was brought to the hospital after suddenly losing consciousness. His son told attending physician that his father is hypertensive but he is not taking his medication regularly. In hospital when he is aroused, he cannot speak and he cannot move his left leg. Which of the following intracranial pathologic abnormalities is most likely to be present?

A. Subarachnoid hemorrhage
B. Basal ganglia hemorrhage
C. Cerebral venous thrombosis
D. Rupture of middle meningeal artery
E. Embolic occlusion of middle cerebral artery

Correct answer : A

55. Patients with insulin resistance syndrome are more likely to develop Alzheimer's disease than the general population because of which one of the following reasons?

A. Increased aggregation of Aβ peptide
B. Decreased clearance of Aβ peptide

C. Presence of extra copy of the APP gene
D. Mutation of presenilin-I
E. Mutation in APP

Correct ans is A

56. Cognitive decline seen in Alzheimer's disease correlates better with the number of:

A. Diffuse plaques
B. Senile plaques
C. Neuritic plaques
D. Neurofibrillary tangles
E. CAG repeats in APP gene

Correct Answer is D

57. The pallor of substantia nigra seen in Parkinson's disease involves loss of which of the following?

A. Melanin
B. Catecholamine
C. Dopamine
D. Serotonin
E. Huntingtin

Correct Answer is A

58. Mutations of which of the following protein-coding genes may result in the development of the autosomal-dominant form of Parkinson disease?

A. α-synuclein
B. Huntingtin
C. APP
D. BDNF
E. Tau

Correct Answer: A

59. Lewy bodies are mainly composed of:

A. Neurofibrillary tangles
B. Diffuse amyloid plaques
C. Dystrophin
D. α-synuclein
E. GABA

Correct Answer: D

60. Which of the following is the most likely pathogen in meningitis in patients older than 50 years of age?

A. Streptococcal pneumoniae
B. N.meningitidis
C. E. coli
D. H. influenza
E. Listeria monocytogenes

Correct Answer is A

61. Which of the following is the cornerstone in the diagnosis of bacterial meningitis?

A. CSF fluid analysis
B. Blood culture
C. CT scan
D. MRI
E. Pharyngeal swab

Correct answer : A

62. Mr. John has suffered from a stroke in the area shown in the figure. He occasionally disregards the left side of the body. Which one of the following cognitive test was advised after reviewing the patient's neuroradiological report?

A. Wisconsin's Sorting Task
B. Go-No-Go Task
C. False-Belief Task
D. Cross the line task
E. Word association task

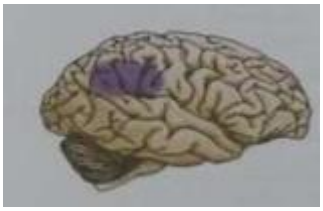

Correct answer : D

63. After the nasty accident, the family of Mr. James noticed that he was making poor decisions. Which of the following cortical regions was most likely affected?

A. Insular cortex
B. Arcuate fasciculus
C. Right inferior temporal gyrus
D. Right parietal cortex
E. Prefrontal cortex

Correct answer : E

64. Subcortical meningioma has left a patient unable to respond appropriately to spoken communication even though speech was well understood. The lesion is most likely present at:

A. Broca's area
B. Wernicke's area
C. Arcuate fasciculus
D. Angular gyrus
E. Exner's area

Correct answer : C

65. A tumor is expanding in the left inferior frontal lobe. Which cognitive deficits would be associated with the lesion?

A. Expressive aphasia
B. Receptive aphasia
C. Agraphia and receptive aphasia
D. Agraphia and expressive aphasia
E. Alexia

Correct answer : A

66. Which cognitive deficit would the patient exhibit with a lesion shown in the Figure of the right hemisphere?

A. Inability to recognize faces
B. Inhibition of inappropriate behavioral tendencies
C. Expressive aphasia
D. Receptive aphasia
E. Emotional coloring of speech

Correct answer : E

67. A patient resuscitated form cardiac arrest for more than a few minutes had no recollection of the events that preceded the cardiac arrest and was unable to recall events some hours after being resuscitated. Which structure of the brain was affected?

A. Dorsolateral prefrontal cortex
B. Orbitofrontal cortex
C. Hippocampus
D. Amygdala
E. Basal ganglia

Correct answer : C

68. After a car accident Mr. John could not remember the immediate events that preceded his accident. What would the most likely diagnosis be?

A. Concussion
B. Retrograde amnesia
C. Anterograde amnesia
D. Transient global amnesia
E. Huntington's disease

Correct answer : A

69. "In which country are the pyramids? ". This question is an example of which memory system?

A. Episodic
B. Working
C. Immediate
D. Semantic
E. Procedural

Correct answer : D

70. Which memory type is affected in Huntington's and Parkinson's disease?

A. Short-term
B. Long-term
C. Declarative
D. Non-declarative
E. Episodic

Correct answer : D

71. Which region of the brain would encode the information depicted in the image?

A. Putamen
B. Hippocampus
C. Amygdala
D. Insula
E. Cingulate cortex

Correct Answer is D

72. A 44-year-old male, who was admitted for selective surgery 3 days before, had developed symptoms of increased agitation, tachycardia, irritability and anger. The most likely diagnosis is:

A. Alcohol withdrawal
B. Diabetes
C. Seizure disorder
D. Major depression
E. Hospital phobia

Correct and is A

73. The following mechanism leads to addiction:

A. Increase serotonin in nucleus accumbens
B. Increase norepinephrine in frontal lobe
C. Increase dopamine in nucleus accumbens
D. Increase the firing of locus coeruleus neurons
E. Increase serotonin in the ventral tegmental area

Correct Answer is C

74. Emotional memory (aversive learning) is mainly stored in:

A. Orbitofrontal cortex
B. Pons
C. Amygdala
D. Dorsolateral prefrontal cortex
E. Anterior cingulate cortex

Correct Answer is C

75. Norepinephrine is secreted in the brain from:

A. Locus coeruleus
B. Prefrontal cortex
C. Dorsal raphe nucleus
D. Ventral tegmental area
E. Amygdala

Correct answer : A

76. The following symptom distinguishes depression from anxiety:

A. Early morning waking
B. Low self-esteem
C. Difficulty falling asleep
D. Decrease interest (anhedonia)
E. Suicidal thoughts

Correct Answer is A

77. A 35-year-old lady developed depressive symptoms after hearing that she is suffering from cancer. The symptoms lasted only for a few days and subsided gradually over one week. She most likely had:

A. Depression
B. Normal reaction
C. Depression secondary to cancer
D. Acute stress disorder

E. Postpartum depression

Correct Answer is B

78. Which of the following is most likely a risk factor to develop depression?

A. Smoking marijuana once a month
B. Diagnosed to have eczema and takes steroids
C. Perfectionistic personality and depressed parents
D. Recently got pregnant and happily married
E. Having normal dizygotic twins

Correct Answer is C

79. A 23-year-old engineering school student has a father with bipolar mood disorder. He now presents with his first depressive episode without any past history of a manic episode. He is best treated with:

A. Fluoxetine
B. Lithium
C. Carbamazepine
D. Lorazepam
E. Paracetamol

Correct Answer is B

80.A 22-year-old woman presenting with irritable mood, grandiosity, pressured speech, distractibility, decreased need for sleep and excessive involvement in high risk behavior. These symptoms occurring for the first time. The most likely diagnosis is:

A. Major depression
B. Bipolar mood disorder
C. Schizophrenia
D. Obsessive compulsive disorder
E. Attention deficit hyperactivity disorder (ADHD)

Correct Answer is B

81. Last night, the media broadcasted a 55-year-old man who committed suicide by gunshot. He most likely has this history:

A. Early dementia
B. Social alcohol drinking
C. narcissistic personality disorder
D. Schizophrenia stable on medication
E. Chronic depression with hopelessness

Correct Answer is E

82. Delirium is a medical emergency that requires immediate management and attention. Which of the following patient scenarios has the highest risk of developing delirium:

A. 25-year-old man with 5 years history of social alcohol drinking
B. 66-year-old man with well-controlled hypertension
C. 81-year-old lady with lung infection
D. 35-year-old pregnant lady, having labour contractions
E. 77-year-old depressed man with normal cognition

The correct Answer is C or E

83. A 60-year-old man presented with fluctuating cognitive function, visual hallucinations, Parkinsonian features and recurrent delirium. This patient most likely has:

A. Alzheimer's dementia
B. Vascular dementia
C. Lewy body dementia
D. Delirium
E. Depression

Correct ans is C

84. 55-year-old man was taking antidepressants but with poor response, presented with impaired concentration and attention, sadness and suicidal thoughts. Lab workup showed normal results except vitamin D deficiency. The most likely diagnosis:

A. Dementia
B. Depression
C. Delirium
D. Anxiety disorder
E. Drug-induced cognitive disorder

The correct Answer is A or B

85. A 77-year-old man has difficulty performing motor tasks like wearing clothes. When instructed to do so, he understands the command but fails to perform the task. This symptom is called:

A. Aphasia
B. Amnesia
C. Agnosia
D. Apraxia
E. Anomia

Correct answer : D

86. A 45-year-old single scientist at a university who is academically functioning well, is medically healthy, works many hours, has no friends and not interested to have sex. His first-degree relatives are most likely to develop:

A. Depression
B. Anxiety disorder
C. Schizophrenia
D. Substance abuse
E. Bipolar mood disorder

Correct Answer is A

87. A 25-year-old single lady who presented with self-harm and suicidal behavior, had unstable relationships, chronic feelings of emptiness and a disturbed identity. She was also impulsive and angry. This personality disordered patient would most benefit from:

A. Antidepressants
B. Mood stabilizers
C. Antipsychotics
D. Psychotherapy
E. Social skills training

Correct Answer is B

88.A 45-year-old male surgeon is highly functioning at work. His family and co-workers complain that he is arrogant, feeling "full of himself", envious and exploit others for his selfish needs. This man most likely has:

A. Narcissistic personality disorder
B. Histrionic personality disorder
C. Paranoid personality disorder
D. Paranoid schizophrenia
E. Grandiose delusions

Correct Answer is A

89. A 33-year-old lawyer is highly functioning in his law office. He is meticulous for detail, underestimates pleasure time, works during holidays and devotes life to his career. He is a perfectionistic. This lawyer has:

A. Schizoid personality disorder
B. Obsessive compulsive personality disorder
C. Obsessive compulsive disorder
D. Antisocial personality disorder
E. Normal personality

Correct Answer is B

90. A 21-year-old female college student who experiences frequent migraine headaches was asking for help. Her headaches were not relieved with other counter analgesics. The neurologist advises that she should start which drug from the following at the first site of pain?

A. Sumatriptan
B. Paracetamol
C. Propranolol
D. Topiramate
E. Verapamil

Correct Answer is A

91. Which of the following is a contraindication for Triptans use?

A. Peptic ulcer disease
B. Diabetes mellitus
C. Hypothyroidism
D. Coronary artery disease
E. Dyslipidemia

Correct Answer is D

92. A 22-year-old male was invited to a rave party. He was tired after a long travel but wanted to attend the party anyway. Which one of the following drugs may help him in energizing, allowing him to attend the all-night long party?

A. Cocaine
B. Khat
C. LSD
D. MDMA
E. Marijuana

Correct Answer is A

93. A 31-year-old university graduate could not find a suitable job after repeated interviews. In some desperate moment, he embarked on a drug of abuse. Soon after taking the drug, he experienced extreme anxiety, dysphoria and became terrorized. The situation became so intolerable that he attempted suicide. Which one of the following drugs might he have taken?

A. Cocaine
B. LSD
C. MDMA
D. Synthetic cathinone
E. Methamphetamine

Correct ans is E

94. Which of the following is the major mechanism underlying currently available antiepileptic drugs?

A. Releasing dopamine pools
B. Blocking sodium or calcium ion channels
C. Blocking GABA neurotransmission
D. Activating glutamate neurotransmission
E. Inhibiting dopamine synthesis

Correct ans is B

95. Which of the following are the main side-effects of first-generation antipsychotics?

A. Acute dyskinesia explained by dopaminergic blocking effect
B. Acute dyskinesia explained by glutamatergic blocking effect
C. Tardive dyskinesia explained by serotonin blocking effect
D. Hypoprolactinemia explained by an adrenergic blocking effect
E. Anxiety explained by the histaminergic blocking effect

Correct Answer is A

96. Which of the following mechanisms applies to second-generation antipsychotics?

A. A higher 5-HT2a receptor occupancy than the first-generation antipsychotics
B. A higher D2 receptor occupancy explaining more dopaminergic side effects
C. Other serotonin receptor occupancies (5-HT1a, 5-HT6, 5-HT7) contributing to a severe weight loss
D. H1 and/or α1 receptor antagonisms explaining frequent motor effects
E. Dopamine transporter inhibition explaining antidepressant effects

Correct Answer is A

97. Which of the following drugs is used in Parkinson's disease treatment?

A. Dopamine, as the endogenous neurotransmitter
B. Pramipexole, as a dopamine receptor agonist
C. Amphetamine, as a dopamine releaser
D. Methylphenidate, as a dopamine transporter inhibitor
E. Memantine, as a glutamate receptor inhibitor

Correct answer : B

98. Which one of the following is one of the mechanisms underlying Alzheimer's drug treatment?

A. Inhibition of acetylcholinesterase
B. Activation of acetylcholinesterase
C. Antagonism of muscarinic cholinergic receptors
D. Glutamate transporter inhibitor
E. Agonism of glutamate NMDA receptors

Correct answer : A

99. Which of the following is true for memantine?

A. It is an irreversible glutamate receptor antagonist
B. It is a reversible glutamate receptor antagonist
C. It improves cognitive functions in the majority of patients
D. It is classically used in patient with mild cognitive impairments
E. Its more frequent side effects involve the GIT

Correct answer : A

100. A 3-year-old child died of encephalitis. MRI and autopsy pictures are provided. The NAAT on the tissue and CSF detected DNA virus. Select the most appropriate statement related to this clinical scenario.

A. Control of the vectors is the major public health measure to prevent additional cases
B. A vaccine should have been useful in preventing the infection
C. Acyclovir should have been administered
D. The CSF would show increased proteins and decreased glucose
E. Rifampicin should be administered for prophylaxis to all close contacts

Correct ans is C

SAQ:

1. A middle-aged woman appeared in the clinic because of difficulties in walking and a sagging of the corner of the mouth. Her history showed that these abnormalities were the latest in the long series of events. Recently, she experienced intermittent painful sensations in the right side of face, and now it has become numb. Within past several weeks, she noticed a tendency to sway to the right while walking. These recent events have been accompanied by difficulty in swallowing and hoarseness. 5 years back, the woman had a series of dizzy spells and complained of tinnitus in the right ear. Somewhat later, she found it difficult to close her eyes tightly, and the corner of the mouth on the right side began to droop and did not rise when she smiled. Neurologic examination revealed a loss of taste in the right side of the tongue. No corneal reflex can be elicited on right side.

A. Locate the site of the lesion and give one justification (2 marks)

Cerebellopontine angle where they are attached to the vestibular branch of the 8th Cranial nerve resulting in tinnitus

B. Name the structures involved in causing following abnormalities seen in this case (10 marks)

Painful sensations in the right side of face → right 5th nerve nuclei
Swaying to the right → inferior cerebellar peduncle
Difficulty in swallowing and hoarseness → 9th and 10th Cranial nerves (nucleus ambiguus)
Tinnitus in the right ear and dizziness → right 8th Cranial nerve
Difficulty closing eyes tightly → right Facial nerve
Sagging of the right side of the face → right facial nerve
Loss of taste in the right side of the tongue → right facial nerve
No corneal reflex → facial efferent and trigeminal afferent (ophthalmic nerve)

C. Define ataxia and tinnitus (4 marks)

Ataxia: uncoordinated body movements
Tinnitus: ringing noise in the ear

D. What is corneal reflex? Why it was lost in this case? (4 marks)

Corneal reflex is the involuntary blinking of the eyelids elicited by the stimulation of the cornea.

Because of the damage to afferent component which is the opthalmic nerve (branch of 5th CN) and the efferent component which is the 7th CN.

2. A 37-year-old man developed involuntary twitching movements in his left thumb. Within 30s, he notices that the twitching has spread to his entire left hand and that involuntary movements have developed in his left forearm and the left side of the face. He cannot recall what happened subsequently, but his wife reports that he fell down and the entire left side of his body appeared to be twitching. He appeared to be unresponsive for about 3 min and confused for another 15 min. During the episode, he bit his tongue and wet his pants. There is no history of head trauma or recent illness.

A. Which part of the motor cortex did this patient's seizure start? Be as specific as you can (2 marks)

The area affected is the primary motor cortex (precentral gyrus), the portion responsible for hand twitching is midway though the primary motor cortex.

B. How would you categorize/classify this type of seizure activity? (2 marks)

It is a focal seizure which then progressed to generalized tonic-clonic seizure.
(an example of Jacksonian march, or sequential seizure)

C. What electroencephalographic wave patterns would you expect to find in this patient during the seizure? (2 marks)

EEG would show seizure waves of 3&2 Hz. with convulsive spike discharge and sharp waves.

D. If this is this patient's first episode, list 3 investigations that might be relevant (3 marks)

Investigation	Rationale
Lumbar puncture	To test for any infections
MRI	To see if there is a lesion in the brain.
Serum electrolytes and glucose	To check for hypo/hypernatremia and hypoglycemia

E. 2 months and 3 similar seizure episodes later, the patient was diagnosed with epilepsy. Name TWO first-line drugs that could be used for treatment. (2 marks)

Phenytoin and Carbamazepine.
This is because the patient experienced both partial and generalized tonic clonic seizure.

F. For the 2 drugs you named above, give 2 adverse effects for each drug (4 marks)

(Pick any 2)
Phenytoin ADR: vertigo, ataxia, nystagmus, confusion, gingival hyperplasia, hirsutism, and folate deficiency
Carbamazepine ADR: drowsiness, ataxia, bone marrow depression

SAQ 7th&6th Batch

Case 1: A case of multiple sclerosis (MS)

A) What is the diagnosis and define this condition?

It is a demyelinating disease which is slowly progressive and a chronic inflammatory disease of uncertain etiology (most likely autoimmune) involving CNS. Disseminated patches of demyelination in brain and spinal cord with varied neurologic symptoms and signs, usually with remissions and exacerbations over many years, followed by gradual, partial recovery of neurologic function. Episodes of neurological deficits are **separated in time, attributable to white matter lesions that are separated in space.**

B) What are the microscopic, gross, MRI and CT findings in this condition?

- **Gross**
  Multiple sharp irregular shaped translucent and firm areas of discoloration (plaques) scattered throughout the **white matter most often affecting the periventricular white matter** in a symmetric fashion involving both hemispheres.
  Affected structures → optic nerve, optic chiasm, brain stem, ascending and descending fiber tracts, cerebellum and spinal cord

- **Microscopic**
  Plaques are characterized by areas of demyelination initially in a perivenous distribution along with variable perivascular lymphocytic inflammatory infiltrate.

a. **Active lesions:** there is loss of myelin sheaths, depletion of oligodendrocytes, fibrillary astrocytosis, and accumulation of lipid-laden macrophages (myelin breakdown products). Axons are relatively preserved but may be reduced in number.

b. **Shadow plaques:** axons invested by abnormally thin faintly staining myelin sheath represent areas of remyelination.

c. **Inactive plaques:** inflammation mostly disappears, leaving behind little to no myelin and reveal astrocytic proliferation and gliosis.

- **MRI**
  Hyperintense patchy areas (of white matter) in periventricular cerebral areas & lesions in cerebellum/brainstem/cervical and thoracic spinal cord.
  Gadolinium enhancement identifies active lesions.
  T2/ FLAIR -hyperintense lesion(s) in cord parenchyma
  Typically no cord expansion (vs. tumor); chronic lesion may show atrophy (Intramedullary)

- **CT**
  Unusually large hypodense plaques are seen by computerized tomography (CT scan). The active plaques all show enhancement after i.v. contrast medium injection, suggestive of blood-brain-barrier-damage, and differ from the well-known CT findings in chronic MS patients, causing diagnostic difficulties between glioma and infarction

C) What is the pathogenesis of this condition?

1. Gene associated with MS is HLA-DRB1*1501
   Polymorphisms in the genes encoding receptors for the cytokines IL-2 and IL-7

2. Autoimmune (immunological): caused by a combination of environmental and genetic factors that result in a loss of tolerance to myelin antigens (MBP) characterized by T cell mediated injury to myelin sheaths and/or oligodendroglial cells. TH1 & TH17 T cells react against myelin antigen and secrete cytokines
   1. CD4 TH1 - IFN gamma - activates macrophages
   2. CD4 TH17 - recruits Leukocytes

3. Molecular mimicry between viral and CNS proteins so that antiviral response is mediated against myelin.

D) What would expect in the CSF Analysis and Evoked Potentials in this patient?

- **CSF analysis will show:**
  Elevated IgG/albumin index (>0.7),
  Mild elevation of proteins,
  Moderate pleocytosis,
  Increased inflammatory cytokines such as, interferon gamma (IFN-ɣ), TNF & IL-2
  Increased activated CD4+ T cells
  Presence of 2 or more distinct oligoclonal bands

- **Evoked potentials**
  Delay in conduction of visual, auditory, and somatosensory information because there is loss of myelin and axonal damage.

E) Prognosis and common cause of death in this case?

Average life span after diagnosis is 25 to 35 years
Suicide rate is 7.5 times higher

Common causes of death:
Compromised swallowing and breathing
Severe infections (e.g. Urosepsis, Aspiration pneumonia)

Case two: MYOCLONIC AND TONIC

Q1: Diagnose

Clonic Epilepsy is described as loss of consciousness with muscle contraction

Q2: Suggest two treatment:
Carbamazepine and Phenytoin

Q3: What is the difference between epilepsy and syncope?

Epilepsy is described as recurrent Seizures provoked by any acute neurological insults .Syncope (We didn't take it by the way) is described as a temporary loss of consciousness usually related to insufficient blood flow to the brain. It's also called fainting or passing out.

Q5: What is the difference between epilepsy and seizure attack

Epilepsy is described as recurrent seizures without any acute neurological insults while seizure is just an overexcitation of Cortical neurons and if it doesn't happen often then it stays as seizures

Q6: List two causes of epilepsy and mention the pathophysiological changes to one of them

Epilepsy can be caused by too much excitation due to release of high amount of NT such as Glutamate and other excitatory ions such as Na+ and calcium and each of the following ions and NT Act on their respective receptors NMDA,etc . It can also happen due to too little inhibition ,that is there is less release of NT such as GABA .The last thing is that it can happen due to inherited mutations in voltage gated ion channel and Ligand gated ion channel

Q7: what are the changes seen in EEG during epileptic attack

EEG would show seizure waves of 3&2 Hz. with convulsive spike discharge and sharp waves.

Case 3: Left Lateral Medullary Syndrome

Q1: What is the diagnosis?

Left lateral medullary syndrome

Q2: Mention the reason for the following symptoms in this case:

A. Ptosis → Damage of sympathetic fibers
B. Soft palate deviation → Vagus nerve damage
C. Loss of pain and temp sensation in the right side of the body → Left lateral spinothalamic tract is affected
D. Increase pain sensation in the left side of the face → Left Spinal Trigeminal nucleus is affected
E. Paralyzed vocal cord → Damage of nucleus ambiguus

Q3: What is the artery involved in this case?
PICA

Case 4:
A 30 year old man experienced weakness in his right leg that worsened over time till he couldn't move it. He also had absent feeling of position and vibration in the right leg till the level of the umbilicus and he had absent sensation of pain and temperature in the left leg. Also he had +ve Babinski sign.

Q1: Which part of the nervous system was involved? Give 2 clues from the case that support your answer.

Hemisection of Spinal cord at the level of umbilicus (T10).
Dorsal Column injury on the right side explains loss of proprioception and vibration.
Injury of the lateral spinothalamic tract explains loss of pain and temperature on the left side below T10 level.
Injury to the anterior horn of spinal cord explains the muscle weakness.

Q2: What is the tract that carries pain and temperature sensation?

Lateral Spinothalamic tract

Q3: Explain briefly the pathway of pain transmission.

Cell bodies of 1st order neuron are in the dorsal root ganglion. Axons will move to the substantia gelatinosa in the spinal cord where cell bodies of 2nd order neuron are and will synapse together. Axons of 2nd order neuron will cross over the midline at the level of the spinal cord and will continue to reach the ventral posterolateral nucleus of the thalamus (VPL) where cell bodies of 3rd order neuron are and will synapse together. Finally, axons of 3rd order neuron will move to the cortex for interpretation of signal (to the primary somatosensory cortex through internal capsule.)

Q4: What is the tract that carries vibration and position sense?

Dorsal Column (Medial Lemniscus) pathway.

Case 5:
A man had a stroke and he was unable to talk fluently, he had slurred slow speech and couldn't move his face and right hand, he had normal forehead furrow. He was able to follow commands like Touch your head with your left hand.

Q1: What artery was involved?

Middle Cerebral Artery.

Q2: What investigations would you do to confirm your diagnosis and why?

MRI → to investigate which area is involved in the stroke and which type of stroke is it.
Angiogram → to identify the artery involved in the stroke.

In case of any mistakes, do not hesitate to contact the EC heads at :

- ★ Khaled Ahmed : kaaahmed@alfaisal.edu
- ★ Raidah A. Razack : rrazack@alfaisal.edu

Exam questions were collected by Exam Committee members and other external contributors.
This document was compiled, edited and revised by Mariam Hendaz. Don't forget us in your Prayers.
We may have done some mistakes, so always refer back to the lectures in case of any doubt. Contact me at mhendaz@alfaisal.edu for any concern. ***Best of Luck!***

Answered by the Exam Committee of the 9th batch

Let's all keep each other in our prayers, cause that's the only thing that can save us in these dire times